

# Chapter 26

## Trends in aesthetic facial surgery: the Hamra lower lid blepharoplasty

Gary L ROSS MB ChB MRCS (Ed) MD FRCS (Plast.) 1

Consultant Plastic Surgeon

David J Whitby MB BS FRCS 2

Consultant Plastic Surgeon

1 CHRISTIE HOSPITAL NHS FOUNDATION TRUST, MANCHESTER, UK

2 UNIVERSITY HOSPITAL OF SOUTH MANCHESTER  
NHS FOUNDATION TRUST, MANCHESTER, UK

### Introduction

The alterations caused by aging are noticeable first around the eyes and then on the neck and lower face. Peri-orbital rejuvenation techniques continue to evolve with a more detailed understanding of eyelid anatomy and the effects of aging on the eyelid and peri-orbital tissues.

Procedures have developed with time, with surgeons striving for a more youthful appearance. The Hamra technique for lower lid blepharoplasty is an example of one such procedure that has evolved over a 30-year period<sup>1-13</sup>.

### Methodology

A Medline search was employed to gather evidence, using the search terms 'lower lid blepharoplasty', 'Hamra technique' and supplemented by a hand search of references from the articles obtained.

### Anatomy of the lower eyelid

The anterior lamella consists of the skin and orbicularis muscle. The middle lamella consists of the orbital septum, which originates from the arcus marginalis and inserts into the inferior tarsal margin. The posterior lamella includes the conjunctiva and lower eyelid retractors<sup>14</sup>.

The orbicularis oculi muscle is immediately deep to the skin of the lower lid and extends from close to the ciliary margin past the infra-orbital rim to the cheek. It has both pretarsal and preseptal components. Pretarsally, the orbicularis is tightly adherent to the underlying tarsus. The pre-orbital portion of the orbicularis oculi has cephalad attachments to the orbital rim along the orbicularis retaining ligament and along its caudal margin to the fascia enveloping the origin of the elevators of the upper lip (zygomaticus muscles). The retaining ligaments that support the orbicularis oculi to the underlying orbital rim and cheek serve to fixate this muscle tightly against the underlying facial framework<sup>15-16</sup>.

The orbital septum lies deep to the orbicularis. A plane of loose connective tissue, the suborbicularis

Trends in aesthetic facial surgery:  
the Hamra lower lid blepharoplasty

fascia, lies between the orbicularis and orbital septum. The suborbicularis oculi fat (SOOF) lies in this plane and is the continuum of the malar fat pad<sup>14</sup>. The triangular malar fat pad has its base at the nasolabial fold and its apex at the malar eminence, and is situated between the skin and the superficial musculo-aponeurotic system (SMAS)<sup>17, 18</sup>. It is loosely connected to the SMAS and firmly attached to the skin.

The orbital septum fuses superiorly with the tarsal plate and inferiorly with the periosteum of the infra-orbital rim; this inferior attachment of the septum is termed the arcus marginalis. The arcus marginalis attaches medially to the anterior lacrimal crest and thins as it extends laterally attaching approximately 2mm inferior to the rim on the facial aspect of the zygomatic bone. The orbital septum serves to retain orbital fat within the orbit. The fat mass, as it encircles the extra-ocular muscles, causes it to be divided into three pads: medial, central and lateral.

## Aging of the lower eyelid-cheek complex

The pathogenesis of herniation of lower orbital fat has been debated for decades<sup>19, 20</sup>. Whether excess fat appears in older age or whether this represents shifting of intra-orbital contents is unclear. The concepts of Manson *et al*<sup>21</sup> and Camirand *et al*<sup>22</sup> attributed lower fat extrusion to a weakening of Lockwood's suspensory ligament with the presence of intra-orbital septation within the fat compartments limiting the degree of protrusion. De la Plaza and Arroyo<sup>23</sup> first proposed the theory that fat protrusion is related to the weakness of the support system of the globe, allowing it to descend and causing enophthalmos and lower lid pseudo-herniation (bags).

The most poorly supported part of the orbicularis oculi is the preseptal portion and it is this that shows the greatest tendency toward descent. As the retaining ligaments relax with aging, the herniated lower lid fat becomes situated not only anteriorly but also inferiorly below the orbital rim. This is most apparent along the central fat pad but may be noted medially as well. It is uncommon to note a lateral fat pad inferior to the infra-orbital rim. In youth, there is no

herniation of orbital fat; the lateral orbicularis oculi blends with the malar pad. Malar bags are rarely apparent and there is a smooth contour between the preseptal and pre-orbital orbicularis. In youth, there is relatively more SOOF in the lower lid and more subcutaneous cheek fat. This helps to make the lower lid appear soft and smooth without the sharp demarcation between eyelid and cheek that become obvious with aging.

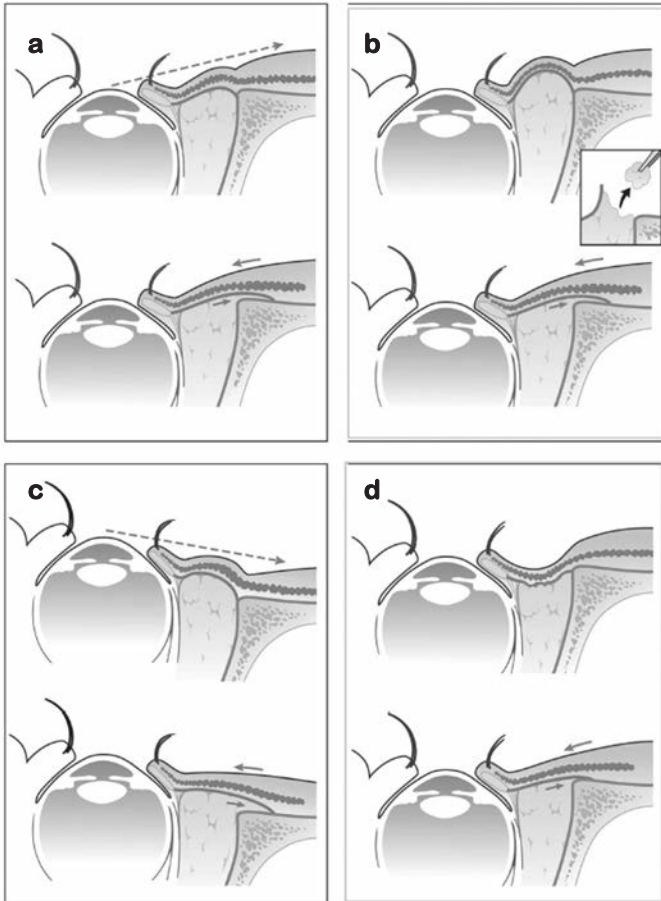
Hamra noted that in youth, the eyelid-cheek complex is a single mildly convex line on profile, running from the tarsus inferiorly over the young cheek. Aging causes descent of the globe and subsequent pseudo-herniation of intra-orbital fat. The inferior and lateral descent of these structures produces an orbit that appears deeper with a wider diameter. This progressive ptosis and attenuation of soft tissue coverage produce skeletonisation of the entire orbital area to reveal the topographical contours of the inferior bony orbital rim. A youthful midface is characterised by a malar fat pad seated over the zygomatic arch, its upper border covering the orbital part of the orbicularis oculi and its inferior border located along the nasolabial fold. With advancing age, the malar fat pad, along with the SOOF, slides in an inferonasal direction and anteriorly over the SMAS. It bulges against the fixed nasolabial crease and exacerbates the appearance of the nasolabial fold.

The combination of descent of the orbicularis oculi, SOOF and malar fat with aging transforms the youthful single convexity to an aging double convex pattern.

## Historical correction of lower lid aging

Historically, lower lid blepharoplasty was viewed as an operation to remove skin and fat in the lower eyelid<sup>19, 20</sup>. The traditional open blepharoplasty redraped the skin or the skin-muscle flap between the infra-orbital rim and the subciliary incision. Orbital fat that appeared excessive was removed, but the 'malar crescent' or inferior border of the orbicularis muscle remained undisturbed from its position over the malar eminence<sup>8, 13</sup>.

Postoperatively, the appearance of the lower eyelid became smoother and usually deeper, particularly in patients with a negative vector. The appearance of the malar crescent or inferior orbicularis border, if present before surgery, remained unchanged. Removal of orbital fat caused eventual collapse of the existing skin

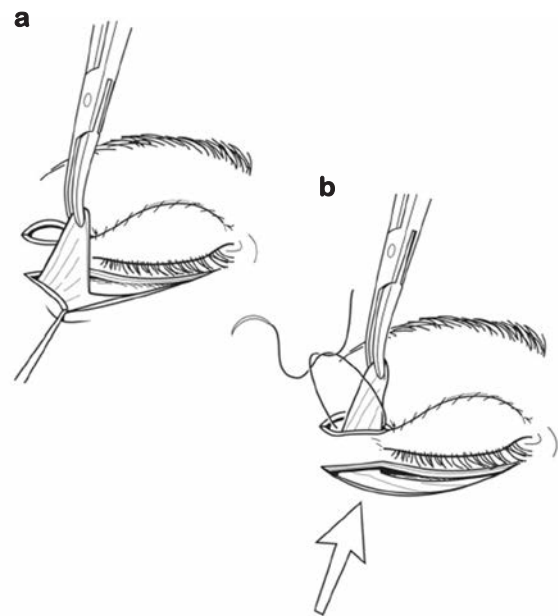


**Figure 1.** a) In patients with a positive vector eye and a normal amount of fat, all fat is preserved when performing the septal reset. The axis drops anterior to the cheek. b) In the event that there is a congenital excess of fat, a certain amount must be excised to prevent postoperative bulging. c) In patients with a negative vector eye, one usually needs to utilise all of the orbital fat to create a smooth transition between eyelid and cheek. The axis drops in a posterior line to the cheek. d) In the hollow lower eyelid, one can always find adequate fat to be recruited from the subseptal space to give an adequate correction. *Reproduced with permission from Lippincott Williams and Wilkins © 2004* <sup>13</sup>.

cover, which created more wrinkling than before. With continuing aging, ptosis and attenuation of the orbicularis oculi led to a typical sunken appearance with possible scleral show <sup>8, 13</sup>.

## Hamra technique (Figures 1 and 2)

This technique aimed to address both the changes in the orbicularis muscle and the orbital fat changes contributing to aging contours.



**Figure 2.** a) A laterally-based flap of orbicularis muscle is created and passed under the lateral raphe. b) The pedicle is attached with two sutures to the lateral orbital periosteum. Extraordinary tension is necessary to effectively elevate and suspend the cheek tissues. *Reproduced with permission from Lippincott Williams and Wilkins © 2004* <sup>13</sup>.

## Repositioning of the orbicularis muscle

The use of the orbicularis muscle as a flap in surgery of the lower eyelid was first described by Adamson *et al* <sup>24</sup>, Courtiss <sup>25</sup> and Furnas <sup>26</sup>, and was first used to treat malar bags/festoons by Furnas <sup>26</sup> advocating lateral tensioning of the orbicularis muscle.

Trends in aesthetic facial surgery:  
the Hamra lower lid blepharoplasty

Hamra <sup>6, 13</sup> noted that by elevating the orbicularis muscle off the malar eminence, in a suborbicularis oculi plane, and repositioning it, the axis of the muscle from the medial orbital rim to the lateral raphe could be changed and the muscular ring around the bony orbit could be tightened. Hamra postulated that to negate the vector of aging in the orbicularis oculi (an inferolateral direction off the malar eminence), the vector of repair should be superomedial <sup>6, 9, 13</sup>. This superomedial vector could either be obtained by a composite rhytidectomy or by using a laterally-based orbicularis muscle flap. The laterally-based orbicularis muscle flap was turned superiorly under the raphe and sutured under extreme tension to the periosteum of the lateral orbital rim <sup>6, 9, 13</sup>.

Hamra <sup>9, 13</sup> noticed limitations of this procedure, which included occasional prolonged malar oedema and an inability to exert sufficient tension on this skin muscle flap owing to the fear of lower eyelid retraction. He thus adapted the plane of dissection to continue the suborbicularis dissection under the medial portions of the zygomaticus minor and major muscles while maintaining an adequate soft tissue cover over the periosteum. With this level of dissection there was no need to disrupt the origins of the zygomaticus musculature while the orbicularis could still be repositioned with even more tension than before <sup>9, 13</sup>. This zygo-orbicular (zygomaticus-orbicularis) plane offered many advantages (Table 1) (III/B). Hamra believes that this zygo-orbicular dissection plane is preferable to the subperiosteal plane as introduced by Tessier <sup>27</sup> and recommended by Hester <sup>28</sup>.

**Table 1. Advantages of zygo-orbicular dissection plane.**

- ◆ Recovery time is shortened with minimal malar oedema and chemosis
- ◆ There is no flap retraction
- ◆ Rapid postoperative adherence between soft tissue and periosteum
- ◆ No temporary orbicularis dystonia
- ◆ No need for a formal canthoplasty
- ◆ The intermalar distance remained the same
- ◆ An arcus marginalis release and septal reset is still possible

Following dissection of the zygo-orbicular flap a 4-0 nylon suture is passed through the longitudinal axis of the lateral canthal tendon which is sutured to the inner wall of the lateral orbital periosteum. This suture stabilises the lower eyelid in yet a higher position, ensuring stability of the eyelid when suturing the septum with adequate tension over the orbital rim. Hamra called this a 'transcanthal' canthopexy, which requires neither detachment of the lateral canthal tendon nor a canthotomy <sup>9, 13</sup>.

### *Preservation of orbital fat/septal reset*

Loeb <sup>29-31</sup> was first to describe the technique of mobilising intra-orbital fat across the medial infra-orbital rim. He used it to fill and thus camouflage the nasojugal groove. Hamra <sup>8</sup> expanded this concept by advocating complete release of the arcus marginalis allowing the subseptal fat to be elevated to the level of the orbital rim. He extended Loeb's concept to include advancement of all of the lower lid fat pads in an effort to conceal the infra-orbital rim and to recreate the youthful fullness of the lower lid. As originally described, the arcus marginalis was incised and the orbital fat alone was advanced and sutured to the preperiosteal fat of the upper cheek. Subsequently, Hamra <sup>13</sup> refined his technique leaving the septum orbitale that he once excised intact and resetting the inferior border of the septum after arcus marginalis release over the orbital rim. The septal flap included orbital fat creating a smoother transition of soft tissue covering the bony rim and a firm smooth convex surface for the redraped overlying skin-muscle flap, thus diminishing the rhytids. Hamra termed this procedure a septal reset. Hamra observed a marked improvement with the repositioned orbicularis now resting on a firm undersurface of septum, rather than on the concavity created by fat removal, or the soft fullness of fat only (III/B).

### *Surgical technique*

Peri-operatively, the dermis of the subciliary incision line is injected with local anaesthesia along with percutaneous injections of a few drops of local anaesthesia with adrenalin layered over the periosteum of the maxilla and zygoma.

The subciliary skin incision is followed by a skin flap dissection to the junction of the preseptal and peri-orbital portions of the orbicularis oculi muscle. The preseptal orbicularis is opened, leaving the pretarsal muscle undisturbed. After dissecting down to the orbital rim over the septum orbitale, the suborbicularis dissection is continued under the zygomaticus muscles. The origins of the zygomaticus major and minor muscles are left intact and an adequate layer of soft tissue is left overlying the periosteum. Dissection is started with cutting cautery and continued with scissors. This dissection prevents potential nerve injury, and pushes the dissection boundary under the midportion of the zygomaticus minor and major, and laterally to the zygomatic arch. The arcus marginalis is released by incising the junction of the septum orbitale and the periosteum of the inferior orbital rim with cutting cautery after the zygo-orbicular dissection has been accomplished. Decisions regarding fat removal or repositioning over the orbital rim are made pre-operatively.

Some medial and central fat may be resected, whereas lateral fat is in most cases used for repositioning. Before the septal reset is completed, a transcanthal canthopexy, with a 4.0 nylon, is undertaken fixing the lower eyelid position so that the septal reset can then be completed without tension. The inferior edge of the septum is then reset over the orbital rim with multiple 5-0 Vicryl sutures. Usually eight to 12 sutures are required for the septal reset to create a smooth transition, ensuring that tension is

sufficient to create a firm undersurface for the orbicularis to rest upon.

After the reset is completed, the zygo-orbicular midface flap is advanced. Several 3-0 Vicryl sutures are placed between the zygo-orbicular flap and the pre-periosteal tissue to reduce dead space and serum collection. A laterally-based orbicularis pedicle is created from the lateral extension of the blepharoplasty incision. This pedicle is passed under the skin and muscle raphe to be secured with two sutures of 4-0 Monocryl to the periosteum of the lateral orbital rim. The very last manoeuvre is the trimming of skin, in the event that an adjustment needs to be made.

### *Fat removal*

Before surgery, the surgeon must decide whether fat must be resected or not, and if so, how much. This is a pre-operative judgement dictated by the anatomy of each individual patient, which is difficult to assess when the patient is anaesthetised. Positive and negative vector eyelids refer to the axis dropped from the most anterior point of the globe to the cheek. The positive vector eyelid is usually the easiest for achieving a good result when using conventional blepharoplasty, and the negative vector eyelid presents a challenge when using conventional blepharoplasty. Hamra defined five groups of patients as illustrated in Table 2<sup>13</sup>.

**Table 2. The five lower eyelid variable types.**

Type	Anatomical variation	Orbital changes	Amount of fat
Type 1	Positive vector	Short vertical height or narrow convex orbit	Normal amount of septal fat
Type 2	Negative vector	Elongated vertical height, or wide concave orbit	Congenital excessive subseptal fat
Type 3	Negative vector	Wide orbit	Normal amount of orbital fat
Type 4	Malar crescent deformity	Wide orbit. Elongated orbicularis	Excess fat
Type 5	The hollow eyelid	Wide orbit	Decrease of orbital fat

Trends in aesthetic facial surgery:  
the Hamra lower lid blepharoplasty

**Table 3. Hamra's grading for optimal results in lower lid blepharoplasty.**

1	Septal reset with zygomaticus-orbicularis repositioning
2	Septal reset. Orbicularis only repositioned
3	Orbital fat transposition done transcutaneously. Orbicularis repositioned
4	Orbital fat transposition done transcutaneously. Orbicularis not repositioned
5	Orbital fat transposition done transconjunctivally. Orbicularis not repositioned

In the case of a positive vector eye with no excess fat, the septal reset takes a small amount of fat with the reset. In the case of a negative vector eye, most of the fat is necessary to adequately fill in the depression between the subciliary line and the cheek mound to create the contour of youth. Patients with a negative vector may also present with a congenital excess of fat. In these cases, conservative fat removal may be appropriate. In the hollow lower eyelid, whether iatrogenic or natural, all possible fat is recruited from the subseptal space to effectively achieve a correction (III/B).

### *Transcutaneous vs transconjunctival*

Proponents of the transconjunctival method argue that it addresses the lower eyelid fullness attributable to prominent orbital fat with a much lower risk of lid retraction, without visible incisions and can be safely combined with resurfacing techniques. The concerns surrounding transcutaneous blepharoplasty are related to middle lamellar contraction/shortening, lateral rounding, scleral show and ectropion. These complications are attributed to violation of the orbicularis, resulting in denervation of the orbicularis oculi. Hamra admits that with the composite lift and repositioning of the orbicularis, partial denervation of the orbicularis can occur<sup>6</sup>, with long-lasting effects<sup>13</sup>. Clinical studies, however, have shown a mixed innervation of the muscle both medially from the buccal branches and laterally from the temporal branch of the facial nerve. Re-innervation to functional normality following surgery has also been

demonstrated<sup>32, 33</sup>. Even studies of orbicularis myomectomies for the treatment of blepharospasm have not produced any long-term denervation or loss of tone<sup>32, 34</sup>.

Honrado's review of 4395 cases defined these patients who may benefit from transconjunctival blepharoplasty, namely the younger patient with smooth skin, moderate fat pseudoherniation and no muscle weakness<sup>35</sup>.

It is generally accepted that the transcutaneous method is required where there is orbicularis hypertrophy, excessive skin, sagging lower eyelids or where canthopexy is required<sup>36</sup>. Transconjunctival methods, however, have also been further adapted to address these issues. A transconjunctival excision of the excess fat may be followed by a transcutaneous approach leaving the orbicularis/septum complex and removing excess skin. Canthoplasty may also be combined with adjuvant resurfacing procedures where required<sup>37-39</sup>. Transconjunctival orbicularis septum tightening using CO<sub>2</sub> laser in combination with peri-ocular skin resurfacing has similarly been reported<sup>40</sup>. It is proposed that leaving the orbicular/septum complex prevents the problems of middle lamellar tightening. Given that lid supporting procedures are so commonly required in association with a transconjunctival approach, whether or not the morbidity of the technique is any less than a transcutaneous procedure is debatable. A system for grading the Hamra blepharoplasty is presented in Table 3<sup>13</sup>.

## ***Reproducibility***

Hamra advocates addressing the lid/cheek complex as part of a composite face lift<sup>1-4</sup>. The isolated Hamra lower lid blepharoplasty technique has not been adopted widely, although its concepts have proved to be reliable and reproducible by others.

Barton *et al*<sup>41</sup> describe its use in the group of patients they label as the 'tear trough triad'. These patients exhibit "fat herniation, prominent orbital rim depression and malar rim retrusion with negative vector" and correspond to Hamra's Type 2/3 patients. They performed the technique in 71 patients showing no middle lamella shortening or contracture. They added that the more extensive infra-orbital dissection disrupts more lymphatic channels draining into the cheek, resulting occasionally in prolonged oedema. In order to avoid this, they used an irrigation solution of triamcinolone into the suborbicularis space before closure and advocate manual lid stretching exercises.

## ***Orbicularis repositioning/transcanthal canthopexy/zygo-orbicular dissection plane***

The optimum plane of dissection has been widely discussed. Hester<sup>28, 42</sup> has recommended a subperiosteal plane based on the work of Tessier<sup>27</sup>, although for patients with pseudoherniation of orbital fat with minimal skin/muscle excess and patients with minimal descent of the lid/cheek junction and malar prominence, a pre-periosteal cheek dissection is sufficient, as it prevents both oedema and downward retraction on the lower lid<sup>42</sup>.

Although Hester *et al* performed a subperiosteal flap dissection, this was combined with arcus marginalis release, transcanthal canthopexy and a laterally-based orbicularis pedicle flap passed under the lateral raphe. This was considered to be an improvement on their original canthotomy and canthoplasty technique<sup>42</sup>. Hamra sees this change in practice as the turning point in the author's quest for a natural look<sup>43</sup>.

Techniques incorporating orbicularis repositioning provide a vertical lift, but they generally result in lateral dog-ear formation, especially in patients with excess skin. Maximal skin removal to address the lateral dog-ear, as recommended by Hester, is often required and is tolerated well with minimal complaints<sup>44</sup>.

## ***Fat repositioning and mobilisation***

Although fat conservation is an increasing trend, debate still centres on fat repositioning (manipulation of the septal fat pads without septal reset) versus fat mobilisation (arcus release and septal reset). Repositioning of the subseptal fat into a subperiosteal pocket is advocated by Goldberg<sup>45</sup>. Repositioning is also advocated by Moelleken rather than a septal reset because of the risk of middle lamellar contracture<sup>14</sup>. Rohrich concludes that Hamra's technique of fat mobilisation is useful in the central and outer portion of the lower eyelid, but falls short in the medial portion, which requires either autologous fat transfer from the central and lateral compartment or autologous fat injection in the suborbicularis plane to soften the medial portion of the nasojugal groove<sup>46</sup>.

## ***Adjuvant resurfacing procedures***

Adjuvant therapies have been used for transcutaneous blepharoplasty, including trichloroacetic acid (TCA) injections/peels, laser resurfacing or fat injections. Hester<sup>42</sup> used TCA or laser resurfacing in over 60% of cases without complications and also proposed fat injection volume restoration in the nasojugal groove. Hamra<sup>43</sup> postulates that improved results would be the same one to two years later with or without adjuvant therapies.

## ***Complications***

Complications following lower blepharoplasty techniques include lateral orbital fullness, canthal webbing, minor scleral show, ectropion, lower lid malposition, prolonged oedema, lateral dog ears and recurrence of the nasojugal groove.

Trends in aesthetic facial surgery:  
the Hamra lower lid blepharoplasty

For significant scleral show/ectropion, Hester recommends canthoplasty. For recalcitrant lower lid malposition, usually with dry eye symptoms not corrected by repeated canthoplasty and re-elevation of the lower lid, Hester *et al*<sup>42</sup> recommended the use of lower lid spacers such as ear cartilage and hard palate mucosa. Hamra recommends alloderm as an alternative<sup>43</sup>.

## Conclusions

The Hamra technique for lower lid blapharoplasty is a personal technique that has evolved over a 30-year period. Adoption of the technique has not been widespread, although it has been shown to be reliable and reproducible. The varying aspects of the technique have been discussed in this review and many individual components of the technique have been widely adopted.

### Recommendations

- | Recommendations                                                                                                                                  | Evidence level |
|--------------------------------------------------------------------------------------------------------------------------------------------------|----------------|
| ◆ Fat repositioning/septal reset creates a smoother transition of soft tissue covering the bony rim and is required to create an optimal result. | III/B          |
| ◆ Fat removal may be appropriate only in carefully selected patients, such as those with a negative vector and a congenital excess of fat.       | III/B          |
| ◆ Repositioning of the orbicularis muscle allows a more appropriate vector and prevents the need for a formal canthoplasty.                      | III/B          |
| ◆ Use of the orbicularis flap does not result in impaired lower lid function.                                                                    | III/B          |
| ◆ Transcanthal canthopexy rather than canthoplasty is recommended for patients requiring lower lid support.                                      | III/B          |

## References

- Hamra ST. Composite rhytidectomy. *Plast Reconstr Surg* 1992; 90: 1-13.
- Lemmon ML, Hamra ST. Skoog rhytidectomy: a five-year experience with 577 patients. *Plast Reconstr Surg* 1980; 65: 283-97.
- Hamra ST. The tri-plane facelift dissection. *Ann Plast Surg* 1984; 12: 268-74.
- Hamra ST. The deep plane rhytidectomy. *Plast Reconstr Surg* 1990; 86: 53-61.
- Hamra ST. A study of the long-term effect of malar fat repositioning in face lift surgery: short-term success but long-term failure. *Plast Reconstr Surg* 2002; 110: 940-51.
- Hamra ST. Repositioning of the orbicularis oculi in composite rhytidectomy. *Plast Reconstr Surg* 1992; 90: 14-22.
- Hamra ST. *Composite Rhytidectomy*. St. Louis, Mo.: Quality Medical Publishing, 1993.
- Hamra ST. Arcus marginalis release and orbital fat preservation in midface rejuvenation. *Plast Reconstr Surg* 1995; 96: 354-62.
- Hamra ST. The zygorbicular dissection in composite rhytidectomy: an ideal midface plane. *Plast Reconstr Surg* 1998; 102: 1646-57.
- Hamra ST. Frequent facelift sequelae: hollow eyes and the lateral sweep: cause and repair. *Plast Reconstr Surg* 1998; 102: 1658-66.
- Hamra ST. Surgical anatomy of the midface and malar mounds. *Plast Reconstr Surg* 2002; 110: 900-5.
- Hamra ST. Correcting the unfavorable outcomes following facelift surgery. *Clin Plast Surg* 2001; 28: 621-38.
- Hamra ST. The role of the septal reset in creating a youthful eyelid-cheek complex in facial rejuvenation. *Plast Reconstr Surg* 2004; 113: 2124-44.
- Moelleken B. The superficial subciliary cheek lift, a technique for rejuvenating the infraorbital region and nasojugal groove: a clinical series of 71 patients. *Plast Reconstr Surg* 1999; 104: 1863-74.
- Mendelson BC, Muzaffar AR, Adams WP, Jr. Surgical anatomy of the midcheek and malar mounds. *Plast Reconstr Surg* 2002; 110: 905-11.
- Muzaffar AR, Mendelson BC, Adams WP, Jr. Surgical anatomy of the ligamentous attachments of the lower lid and lateral canthus. *Plast Reconstr Surg* 2002; 110: 873-84.



17. Mitz V, Peyronie M. The superficial musculoaponeurotic system (SMAS) in the parotid and cheek area. *Plast Reconstr Surg* 1976; 58: 80-8.
18. De Cordier BC, de la Torre JI, Al-Hakeem MS, et al. Rejuvenation of the midface by elevating the malar fat pad: review of technique, cases, and complications. *Plast Reconstr Surg* 2002; 110: 1526-36.
19. Bourget J. Les hernies graisseuses de l'orbite: notre traitement chirurgical. *Bull Acad Med (Paris)* 1924; 92: 1270.
20. Castanares S. Blepharoplasty for herniated intraorbital fat: anatomical basis for a new approach. *Plast Reconstr Surg* 1951; 8: 46-58.
21. Manson PN, Clifford CM, Su CT, et al. Mechanisms of global support and post-traumatic enophthalmos: I. The anatomy of the ligament sling and its relation to intramuscular cone orbital fat. *Plast Reconstr Surg* 1986; 77: 193-202.
22. Camirand A, Doucet J, Harris J. Anatomy, pathophysiology, and prevention of senile enophthalmia and associated herniated lower eyelids. *Plast Reconstr Surg* 1997; 100: 1535-46.
23. de la Plaza R, Arroyo JM. A new technique for the treatment of palpebral bags. *Plast Reconstr Surg* 1988; 81: 677-87.
24. Adamson JE, McCraw JB, Carraway JH. Use of a muscle flap in lower blepharoplasty. *Plast Reconstr Surg* 1979; 63: 359-63.
25. Courtiss EH. Selection of alternatives in esthetic blepharoplasty. *Clin Plast Surg* 1981; 8: 739-55.
26. Furnas DW. The orbicularis oculi muscle. Management in blepharoplasty. *Clin Plast Surg* 1981; 8: 687-715.
27. Tessier P. Le lifting faciale sousperioste. *Ann Chir Plast Esthet* 1989; 34: 193-7.
28. Hester TR, Codner MA, McCord CD. The 'centrofacial' approach for correction of facial aging using the transblepharoplasty subperiosteal cheeklift. *Aesthetic Surg J* 1996; 16: 51-8.
29. Loeb R, Ed. *Aesthetic Surgery of the Eyelids*. New York: Springer-Verlag, 1989.
30. Loeb R. Nasojugal groove leveling with fat tissue. *Clin Plast Surg* 1993; 20: 393-400.
31. Loeb R. Fat pad sliding and fat grafting for leveling lid depressions. *Clin Plast Surg* 1981; 8: 757-76.
32. Hester TR, McCord CD, Nahai F, et al. Expanded applications for transconjunctival lower lid blepharoplasty. *Plast Reconstr Surg* 2001; 108: 271-2.
33. Lowry JC, Bartley GB, Litchy WJ. Results of levator-advancement blepharoptosis repair using a standard protocol: effect of epinephrine-induced eyelid position change. *Trans Am Ophthalmol Soc* 1996; 94: 165-73.
34. McCord CD Jr, Shore J, Putnam JR. Treatment of essential blepharospasm. II. A modification of exposure for the muscle stripping technique. *Arch Ophthalmol* 1984; 102: 269-73.
35. Honrado CP, Pastorek NJ. Long-term results of lower-lid suspension blepharoplasty: a 30-year experience. *Arch Facial Plast Surg* 2004; 6: 150-4.
36. Rizk SS, Matarasso A. Lower eyelid blepharoplasty: analysis of indications and the treatment of 100 patients. *Plast Reconstr Surg* 2003; 111: 1299-306.
37. Patipa M. Transblepharoplasty lower eyelid and midface rejuvenation: part I. Avoiding complications by utilizing lessons learned from the treatment of complications. *Plast Reconstr Surg* 2004; 113: 1459-68.
38. Patipa M. Transblepharoplasty lower eyelid and midface rejuvenation: part II. Functional applications of midface elevation. *Plast Reconstr Surg* 2004; 113: 1469-74.
39. Zarem HA, Resnick JI. Expanded applications for transconjunctival lower lid blepharoplasty. *Plast Reconstr Surg* 1999; 103: 1041-3.
40. Seckel BR, Kovanda CJ, Cetrulo CL Jr, Passmore AK, Meneses PG, White T. Laser blepharoplasty with transconjunctival orbicularis muscle/septum tightening and periocular skin resurfacing: a safe and advantageous technique. *Plast Reconstr Surg* 2000; 106: 1127-41.
41. Barton FE, Ha R, Awada M. Fat extrusion and septal reset in patients with the tear trough triad: a critical appraisal. *Plast Reconstr Surg* 2004; 113: 2115-21.
42. Hester TR, Codner MA, McCord CD, et al. Evolution of technique of the direct transblepharoplasty approach for the correction of lower lid and midfacial aging: maximizing results and minimizing complications in a 5-year experience. *Plast Reconstr Surg* 2000; 105: 393-406.
43. Hamra ST. Evolution of technique of the direct transblepharoplasty approach for the correction of lower lid and midfacial aging: maximizing results and minimizing complications in a 5-year experience. *Plast Reconstr Surg* 2000; 105: 407-8.
44. Labandter HP. Use of the orbicularis muscle flap for complex lower lid problems: a 6-year analysis. *Plast Reconstr Surg* 1995; 96: 346-53.
45. Goldberg RA. Transconjunctival orbital fat repositioning: transposition of orbital fat pedicles into a subperiosteal pocket. *Plast Reconstr Surg* 2000; 105: 743-8.
46. Rohrich RJ. The superficial subciliary cheek lift, a technique for rejuvenating the infraorbital region and nasojugal groove: a clinical series of 71 patients. *Plast Reconstr Surg* 1999; 104: 1875-6.

Trends in aesthetic facial surgery:  
the Hamra lower lid blepharoplasty